

See discussions, stats, and author profiles for this publication at: <https://www.researchgate.net/publication/5625623>

Comparative efficiency of intraperitoneal interleukine-2 and interferon-A in rats with experimental endometriosis

Article in *Bulletin of Experimental Biology and Medicine* · April 2007

DOI: 10.1007/s10517-007-0113-z · Source: PubMed

CITATIONS

10

READS

17

2 authors, including:



Sergey Alekseevitch Selkov

D. O. Ott Research Institute of Obstetrics and Gynecology

154 PUBLICATIONS 324 CITATIONS

SEE PROFILE

Some of the authors of this publication are also working on these related projects:



Labor & pregnancy in diabetes melites [View project](#)



Prevention of reproductive failure in women with thrombophilia [View project](#)

Comparative Efficiency of Intraperitoneal Interleukine-2 and Interferon- α in Rats with Experimental Endometriosis

S. A. Sel'kov and R. V. Pavlov

Translated from *Byulleten' Eksperimental'noi Biologii i Meditsiny*, Vol. 143, No. 3, pp. 335-339, March, 2007
Original article submitted June 13, 2006

Intraperitoneal injection of rat IFN- α and human IL-2 to rats with experimental endometriosis led to complete regression of endometrioid heterotopies in 50 and 60% cases, respectively. Retention of the endometrioid epithelium resulted in a significant reduction of proliferative activity of its cells, degree of vascularization, and number of macrophages in the leukocytic infiltration of endometrioid heterotopies.

Key Words: *endometriosis; treatment; interferon; interleukine-2*

Endometriosis ranks among the first in the structure of gynecological morbidity. The etiology and pathogenesis of this disease remain little studied [2].

More and more data attest to an important role of disorders in local immune response in the development of external genital endometriosis. For example, it was found that the count and functional activity of peritoneal fluid macrophages increased in patients with endometriosis, which was paralleled by decreased activity of natural killer cells and cytotoxic T lymphocytes [3-8]. Therefore, the possibility of selective stimulation of defense functions of immunocompetent cells with activating cytokines and their combinations in patients with external genital endometriosis is an important problem.

Clinical trials of immunomodulating drugs for the treatment of endometriosis were carried out [6,8]. However, the mechanism leading to regression of endometrioid heterotopies during immunomodulating therapy remains not quite clear.

We compared the efficiency of intraperitoneal injections of IL-2 and IFN- α_2 (activating cytokines) in the treatment of external genital endometriosis in

rats and studied possible mechanisms leading to regression of endometrioid heterotopies.

MATERIALS AND METHODS

Experimental endometriosis (EE) was reproduced in 60 female Wistar rats by autotransplantation of fragments of the left uterine horn onto the inner surface of the anterior abdominal wall (endometrium faced the abdominal cavity). All surgical interventions were carried out under pentobarbital narcosis (50 mg/kg). Absorbable thread (Biosorb 6.0; Alcon Surgical) was used. Ten days after transplantation of the uterine horns, the animals were divided into 3 groups.

Group 1 rats ($n=20$) received 3 injections (with 1-day intervals) of human recombinant yeast IL-2 (Biotech) in a dose of 8000 U/kg (converted from the mean dose for humans of 500,000 U) into the abdominal cavity under aseptic conditions.

Group 2 animals ($n=20$) received 3 injections (with 1-day intervals) of rat recombinant IFN- α (Sigma-Aldrich) in a dose of 15,000 U/kg (converted from the mean dose for humans of 1×10^6 U) into the abdominal cavity under aseptic conditions.

Group 3 ($n=20$; control) animals received sterile saline injections into the abdominal cavity under aseptic conditions according to the same protocol.

Laboratory of Immunology, D. O. Ott Institute of Obstetrics and Gynecology, Russian Academy of Medical Sciences, St. Petersburg; Department of Obstetrics and Gynecology, Stavropol State Medical Academy

All animals were sacrificed 40 days after the start of the experiment; EE foci were examined visually and their histological structure was evaluated. Proliferative activity of endometrioid gland epithelial cells and vascular endotheliocytes in EE foci was evaluated by the following criteria: area of nuclei, cell ploidy, and activity of nucleolar organizer regions (NOR) [1]. Vascularization of EE foci was evaluated by the summary area of vessels and mean capillary lumen, activity of angiogenesis was evaluated by the morphological criteria of proliferation of capillary endotheliocytes.

For evaluation of vascularization of EE foci, karyometry, estimation of the main populations of immunocompetent cells, and evaluation of NOR activity the sections were stained with hematoxylin and eosin, by the method of Romanowsky—Giemsa, with acridine orange, and impregnated with silver nitrate.

Systemic morphometric analysis of remote EE foci was carried out using microtelephotometric image analyzer consisting of VKM 380 videocam, LUMAM P-8 polyfunctional microscope, block for digital processing of images, and Pentium III computer with VideoTest-Morpho software (Istra-VideoTest).

RESULTS

Comparison of macroscopic characteristics of EE foci (Fig. 1) showed white foci and decreased incidence of red foci in groups 1 and 2.

Microscopy showed foci of typical endometrioid epithelium in EE areas in all animals of the control group, which indicated the development of EE in all cases. No ectopic endometrium was detected in endometriosis zone in 12 rats (60.0%) of group 1 and 10 rats (50.0%) of group 2, which indicated regression of endometrioid heterotopias. Complete replacement of EE focus with granulation tissue was observed in 9 rats of group 1 and in 5 rats of group 2, multicystic degeneration of EE area was detected in similar numbers of animals (in 3 in group 1 and in 2 in group 2), necrosis of EE focus was not observed in group 1, but was detected in 2 animals in group 2 (Fig. 2).

Morphometry showed that irrespective of the drug, the volume of EE foci and area of retained endometrioid glands in treated animals were significantly lower than in group 3 (Fig. 3). Evaluation of the area of nuclei, height of the epithelium, ectopic endometrial cell ploidy, and NOR activity in their nuclei showed a significant reduction of all

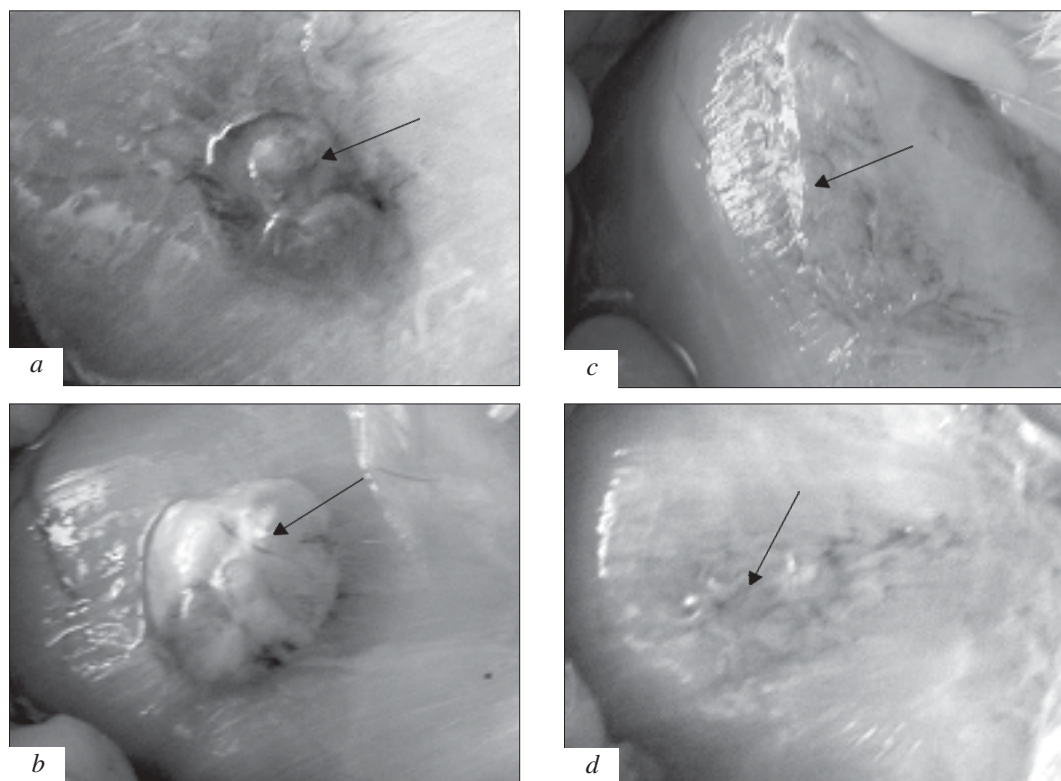


Fig. 1. Macroscopic characteristics of EE zones in animals treated with different drugs. *a*) red focus of endometriosis (group 3); *b*) cyst on the transplant surface (group 3); *c*) white focus of endometriosis (group 1); *d*) white focus of endometriosis (group 2).

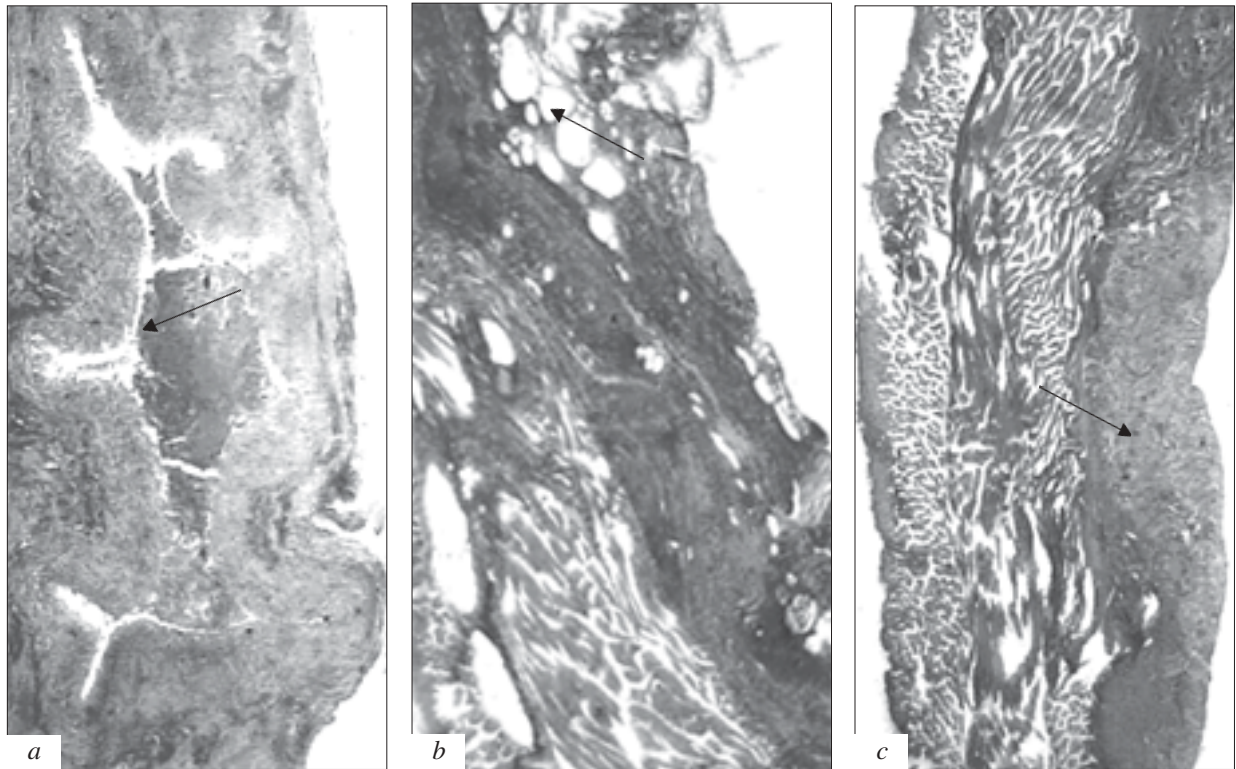


Fig. 2. Variants of endometriosis foci regression in groups treated with different drugs. Arrows show: a) transplant necrosis (group 2); b) multicystic degeneration of endometriosis focus (group 2); c) replacement of endometriosis focus by granulation tissue (group 1). Here and in Fig. 3: hematoxylin and eosin staining, $\times 40$.

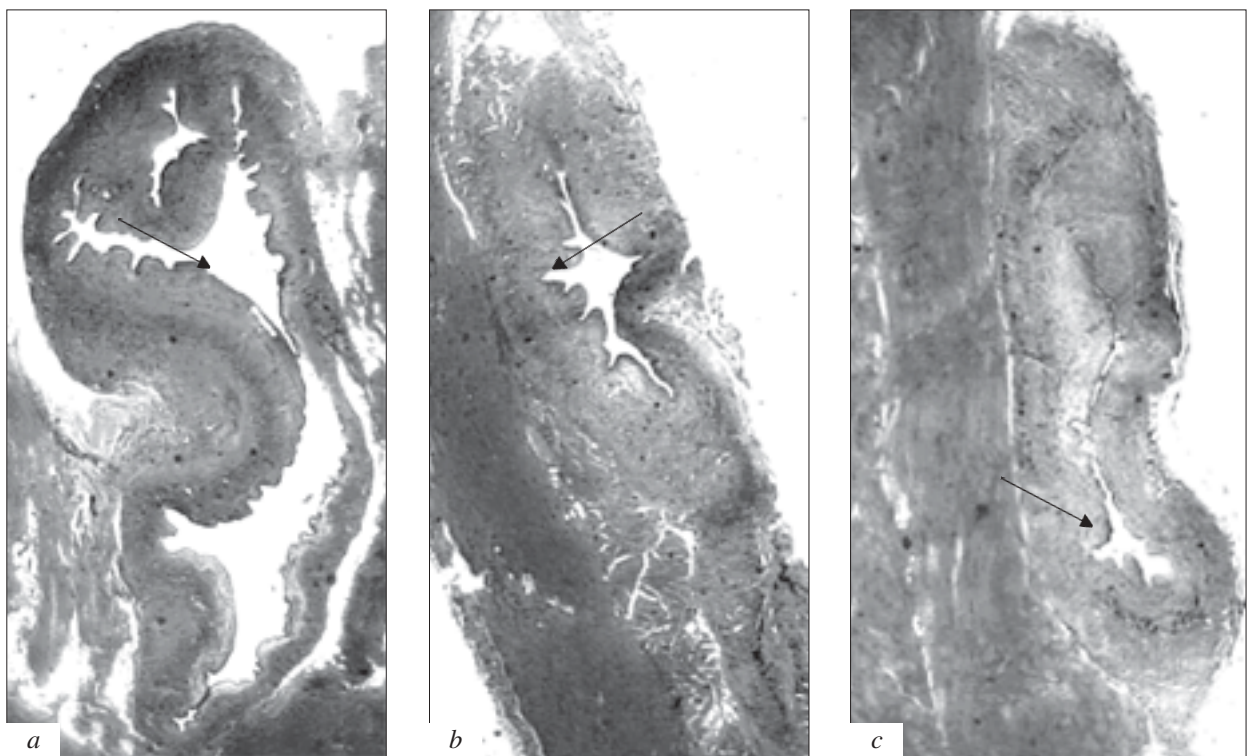


Fig. 3. Microscopic picture of endometriosis zones with intact epithelium in animals receiving different preparations. Arrows show: transplant and endometrioid gland in group 3 (a); decreased volume of the transplant and area of the endometrioid gland in groups 1 (b) and 2 (c).

TABLE 1. Proliferative Activity of Epithelial Cells in Endometrioid Heterotopies ($M\pm m$)

Parameter	Group 1 (n=8)	Group 2 (n=12)	Group 3 (n=20)
Height of epithelium, μ	8.68 \pm 0.58***	10.90 \pm 0.86***	14.10 \pm 0.74
Area of epitheliocyte nuclei, μ^2	15.58 \pm 1.44**	15.00 \pm 0.97***	19.97 \pm 0.76
Epitheliocyte ploidy, DNA content per cell, c	2.49 \pm 0.25*	2.38 \pm 0.13**	3.35 \pm 0.32
Number of NOR in nucleus	2.05 \pm 0.07*	2.10 \pm 0.12*	2.63 \pm 0.16
Mean area of NOR, μ^2	1.06 \pm 0.04***	1.36 \pm 0.08**	1.61 \pm 0.09 ⁺
Summary area of NOR, μ^2	2.11 \pm 0.10**	2.42 \pm 0.08***	3.17 \pm 0.32

Note. Here and in Tables 2, 3: * p <0.05, ** p <0.01, *** p <0.001 compared to group 3; ⁺ p <0.05, ⁺⁺ p <0.01 compared to group 1.

TABLE 2. Vascularization of Endometrioid Heterotopies ($M\pm m$)

Parameter	Group 1 (n=20)	Group 2 (n=20)	Group 3 (n=20)
Percent of vascular lumen area from transplant area	8.11 \pm 0.95*	8.00 \pm 1.00*	10.79 \pm 0.70
Mean capillary lumen, μ^2	77.30 \pm 6.00**	63.38 \pm 5.53***	107.97 \pm 9.73
Epitheliocyte nuclei area, μ^2	8.69 \pm 0.36*	7.91 \pm 0.41***	10.33 \pm 0.54
Epitheliocyte ploidy, DNA content per cell, c	2.04 \pm 0.07*	2.02 \pm 0.06*	2.28 \pm 0.09
Number of NOR in nucleus	1.88 \pm 0.19	1.77 \pm 0.18	1.98 \pm 0.11
Mean area of NOR, μ^2	0.53 \pm 0.05*	0.54 \pm 0.04*	0.74 \pm 0.09
Summary area of NOR, μ^2	0.86 \pm 0.11***	0.83 \pm 0.05***	1.35 \pm 0.08

TABLE 3. Cell Composition of Leukocyte Infiltration in Endometrioid Heterotopies and Peritoneal Fluid ($M\pm m$)

Parameter	Group 1 (n=20)	Group 2 (n=20)	Group 3 (n=20)
Leukocytes per 1 mm ²	3697.00 \pm 308.60***	4932.00 \pm 396.80****	1863.00 \pm 359.00
Neutrophils, %	2.09 \pm 0.37*	3.18 \pm 0.32	3.36 \pm 0.92
Mast cells, %	1.28 \pm 0.28*	1.54 \pm 0.40*	2.95 \pm 0.58
Macrophages, %	0.83 \pm 0.17***	1.29 \pm 0.14**	2.00 \pm 0.25
Lymphocytes, %	95.80 \pm 2.35**	93.99 \pm 1.37*	91.69 \pm 3.95

parameters reflecting proliferative activity of epithelial cells in EE foci of treated rats. The height of ectopic epithelium and NOR area in the nuclei of its cells were significantly lower in animals treated with IL-2 (Table 1).

Analysis of vascularization of EE foci showed a significant reduction in the summary area of the vascular bed, mean area of capillary lumen, areas of endotheliocyte nuclei, endothelial cell ploidy, and NOR activity in endotheliocyte nuclei of animals treated with IL-2 and IFN- α , the degree of this reduction not depended on the drug (Table 2).

Treatment with IL-2 and especially with IFN- α intensified leukocytic infiltration of endometrioid heterotopies. Not only the intensity of leukocytic infiltration increased in the EE focus; its qualitative composition also changed (lymphocyte count significantly increased, while the counts of macropha-

ges, mast cells, and neutrophils decreased). IFN- α more markedly reduced the count of macrophages in leukocytic infiltration compared to IL-2 (Table 3).

Analysis of the results indicated that intraperitoneal treatment with IFN- α and IL-2 led to complete regression of EE foci in 50 and 60% animals, respectively. The volume of EE foci decreased significantly in remaining endometrioid glands; proliferative activity of ectopic endometrial cells decreased. These data suggest that the action of IFN- α and IL-2 in regression of EE can be mediated through activation of lymphocytes infiltrating endometriosis foci and exhibiting a direct cytotoxic effect on ectopic endometrium cells in parallel with reduced counts of macrophages initiating the angiogenesis processes. Decreased vascularization of EE foci and reduced activity of endothelial cells as a result of treatment are additional proofs in favor of this

hypothesis. The reduction of proliferative activity of ectopic endometrial cells after IL-2 treatment was more pronounced; there was no local side effect (necrosis of EE foci). On the other hand, lower (in comparison with IL-2) efficiency of IFN- α was due to short period of treatment. It is known that therapy of tumor processes and chronic viral infections requires long, some times for many months, IFN treatment. Presumably, external genital endometriosis, as a chronic disease with dysregulation of cell proliferation, also requires long-term IFN therapy for attaining a stable clinical morphological effect, in other words, an intraperitoneal injection of IFN- α should be supplemented by a long-term course of intramuscular or subcutaneous injections of the preparation.

REFERENCES

1. G. G. Avtandilov, *Computer-Aided Microtelephotometry in Diagnostic Histocytopathology* [in Russian], Moscow (1996).
2. L. V. Adamyana and V. I. Kulakov, *Endometriosis: Manual for Physicians* [in Russian], Moscow (1998).
3. G. M. Makhmudova and A. V. Popov, *Ros. Vestn. Akush. Ginekol.*, No. 2, 27-30 (2004).
4. S. A. Sel'kov, N. L. Kramareva, O. V. Pavlov, and M. I. Yarmolinskaya, *Zh. Akush. Zhensk. Bol.*, **51**, No. 3, 57-62 (2002).
5. M. I. Yarmolinskaya, V. V. Grigoryeva, V. B. Anikin, *et al.*, *Immunol. Reprod.*, **6**, Nos. 3-5, 394-395 (2004).
6. M. Berkanoglu and A. Arici, *Am. J. Reprod. Immunol.*, **50**, No. 1, 48-59 (2003).
7. W. Paul Dmowski and D. P. Braun, *Best Pract. Res. Clin. Obstet. Gynaecol.*, **18**, No. 2, 245-263 (2004).
8. M. Y. Wu and H. N. Ho, *Am. J. Reprod. Immunol.*, **49**, No. 5, 285-296 (2003).