

UDK 61.617.612.089

## FROM THE PRACTICE OF TREATING PATIENTS WITH ACUTE ODONTOGENIC INFECTION AT THE HOSPITAL STAGE

**O.D. Maday,**

Candidate of Medical Sciences, Associate Professor of the Department of Maxillofacial Surgery and Surgical Dentistry

**D.Yu. Maday,**

MD, Professor, Honored Doctor of the Russian Federation, Head of the Department of Maxillofacial Surgery and Surgical Dentistry

**Yu.A. Shcherbuk,**

MD, Professor, Academician of the Russian Academy of Sciences, Head of the Department of Neurosurgery and Neurology

**V.K. Kozlov,**

MD, Professor, Professor of the Department of Maxillofacial Surgery and Surgical Dentistry,

St. Petersburg State University,  
St. Petersburg

**Annotation:** For modern surgery the treatment of mediastinitis is one of the most difficult to solve. Foci of inflammation in the periapical tissues of the teeth, tonsils and mucous membrane of the oral cavity are the primary source of infection of phlegmons of the deep cellular spaces of the neck, the course of which can be complicated by the development of mediastinitis. The article describes a clinical case of successful treatment of odontogenic phlegmon of the maxillofacial region, deep spaces of the neck, complicated by mediastinitis.

**Keywords:** odontogenic infection, phlegmon of the maxillofacial region, odontogenic mediastinitis

The problem of acute odontogenic infection in the practice of dental surgeons and maxillofacial surgeons remains relevant to this day. This is due to the complexity of anatomical formations and high functional significance of facial organs and tissues, the increase of patients with purulent-inflammatory diseases of the maxillofacial region in the medical dental and maxillofacial institutions [2]. It is also important to note that this

group of hospitalized patients is the most complex and numerous, which requires urgent and often emergency care [1].

For modern surgery the treatment of mediastinitis is one of the most difficult to solve [1, 4]. Foci of inflammation in the periapical tissues of the teeth, tonsils and mucous membrane of the oral cavity are the primary source of infection of phlegmons of the deep cellular spaces of the neck, the course of which can be complicated by the development of mediastinitis [3]. In the initial period of mediastinitis development, clinical symptoms hide behind the picture of the inflammatory process in the neck and lose their specificity that leads to late diagnosis of this bad complication. In this regard, the mortality rate in mediastinitis reaches almost 50 % [4, 5].

The purpose of this work is to present clinical observation of odontogenic sepsis that occurred against the background of an acute odontogenic limited osteomyelitis of the upper jaw from the 2.7 tooth, the phlegmon of the left pterygoid -maxillary, the left temporal, pterygoid-palatine fossa, the left subtemporal, perilaryngeal, chewing spaces that leads to recovery.

Patient L., born in 1976, was admitted to the «Clinical Hospital «Russian Railways-Medicine» of St. Petersburg» (base of the Department of Maxillofacial Surgery and Surgical Dentistry of St. Petersburg State University) on 02.02.2018 at 17:30 with the diagnosis «an acute odontogenic limited osteomyelitis of the upper jaw from tooth 2.7, phlegmon of the left subtemporal, temporal, pterygoid-palatine fossa». Upon admission, he complained of constant pain in the upper jaw on the left, swelling of the face on the left, difficult opening of the mouth, general weakness and fatigue.

According to the patient he was ill for 5 days. The onset of the disease was associated with the removal of the 2.7 tooth in a private clinic in St. Petersburg on 28.01.2018 when he began to notice the growth of swelling of the left cheek. He took Nimesulide tablets on his own. On 30.01.2018 edema spread up and difficult opening of the mouth appeared and began to increase with general weakness.

01.02.2018 he consulted the dental surgeon for the second time who prescribed the following treatment: Chemomycin tablets (Azithromycin), Metronidazole tablets, physiotherapy procedures for the left half of the face.

Gradually the condition got worse. On 02.02.2018 he felt that his symptoms became more pronounced and he was sent by a dental surgeon to the «Clinical Hospital «of Russian Railways-Medicine» of St. Petersburg» for hospitalization.

During hospitalization the general condition of a patient was severe, respiratory and cardiovascular systems were without features: heart rate is 76 beats per minute, blood pressure 135/85 mm Hg, frequency of respiratory movements 18 per minute; body temperature 37.5 °C. The face was pale, above and under the left zygomatic arch there was a moderately pronounced edema, dense pain infiltrate. The skin above it was hyperemic. Opening of the mouth was painful, limited to 1 cm, swallowing was not difficult. In the mouth cavity: the hole of the tooth 2.7 under fibrinous plaque, there was a pronounced swelling and hyperemia of the surrounding mucous membrane, upper transition fold, left pterygoid-maxillary fold, palpation caused the entry of pus separated from the hole of the tooth 2.7 with an unpleasant, ichorous smell. The mouth cavity was not sanitized. Preliminary diagnosis: «an acute odontogenic limited osteomyelitis of the upper jaw from the tooth 2.7. Phlegmon of the left subtemporal, temporal, pterygoid-palatine fossa». A decision was made to open and drain the focus of odontogenic polyphlegmon (left subtemporal, temporal, pterygoid-palatine fossa) under general anesthesia (neuroleptanalgesia with intubation of the trachea through the nose with endoscopic assistance). On 02.02.2018 at 18:05, the operation was performed: «opening and drainage of phlegmon of the left subtemporal, temporal, pterygoid-palatine fossa». The subaponeurotic temporal space, the subtemporal fossa, the fat body of the cheek on the left and the left pterygoid-palatine fossa were opened under general anesthesia, through incisions in the left temporal region above the zygomatic arch and a cut in the mouth along the upper transitional fold of the left. The cellular tissue was infiltrated, partially dead. 10 ml of liquid pus was obtained. The wound was thoroughly washed with antiseptic solutions and drained with polyvinyl chloride tubes. An aseptic dressing was applied. Curettage of the hole of the removed 2.7 tooth was performed, the hole was thoroughly washed with an antiseptic solution (figure 1). In the blood analysis from 02.02.2018 – leukocytosis ( $19.0 \times 10^9/L$ ) with a rod – shaped shift to the left, acceleration of ERS to 56 mm/h, in the biochemical analysis of blood from 02.02.2018-hyperglycemia (7.6 mmol/L). The patient was admitted for further observation and treatment to

the Department of anesthesiology, resuscitation and intensive care of the «Clinical Hospital «of Russian Railways-Medicine» of St. Petersburg».

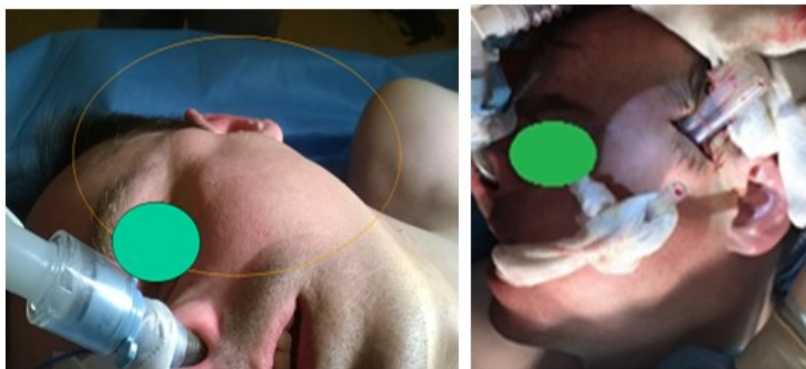

Figure 1 – External appearance of patient L. before the first operation on the day of admission (left); patient L. after opening of odontogenic phlegmon of the left subtemporal, temporal, pterygoid-palatine fossa: the subtemporal and pterygoid- palatine fossa are drained (right)

In the postoperative period an antibacterial therapy (Sultasin, Metrogil, Amikacin) was performed on the first day of admission in the Department of anesthesiology, resuscitation and intensive care. To improve microcirculation Reamberin was administered, Cordarone was administered to prevent arrhythmia and Tranexam was prescribed to prevent postoperative bleeding. Fragmin was used to prevent thrombosis. Kvamatel was used as a desensitizing agent. Furosemide was prescribed to prevent kidney failure as well as to achieve detoxification. For the purpose of sedation and anesthesia the patient received Ketamine, Relanium and Fentanyl. The patient's condition was severe, due to endogenous intoxication, the volume of surgery.

03.02.2018 at 09: 30, the patient's condition worsened: the edema spread to the left side surface of the neck, the skin above the edema was tense, moderately hyperemic, the skin temperature above the edema was slightly increased. Finger examination of the wound channels determined the flow of the wound separated into the surrounding soft tissues, when examining soft tissues their consistency was noted like «boiled meat». The spread of the inflammatory process in the perilaryngeal, chewing space on

the left was suspected. In an emergency the second operation was performed under general anesthesia: «opening and drainage of phlegmon of the left perilaryngeal, chewing spaces, parotid-chewing region, revision of the left subtemporal, temporal, pterygoid-palatine fossa». When dissecting, soft tissues were extremely pliable, bleeding slightly and had an unpleasant smell. Gas bubbles were detected in the tissues and a slight vague discharge with a greasy shine was detected from the wound. Wounds were thoroughly washed with antiseptic solutions and drained with polyvinyl chloride tubes (fig. 2), aseptic bandages were applied.

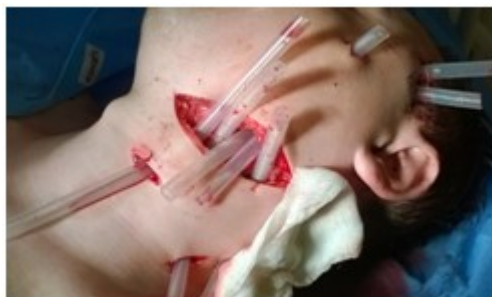

Figure 2 – External appearance of patient L. after the second operation: drained perilaryngeal, chewing regions on the left, left parotid-chewing region, subtemporal, temporal, pterygoid-palatine fossa on the left

When examined after the operation at 12:40 a deterioration in condition was noted. Locally, there was the growth of edema of the left supraclavicular region without signs of hyperemia and local temperature increase, palpation determined crepitation in this area. Spiral computed tomography of the neck and chest was performed in extreme order: gas accumulation in the anterior-upper mediastinum (fig. 3).

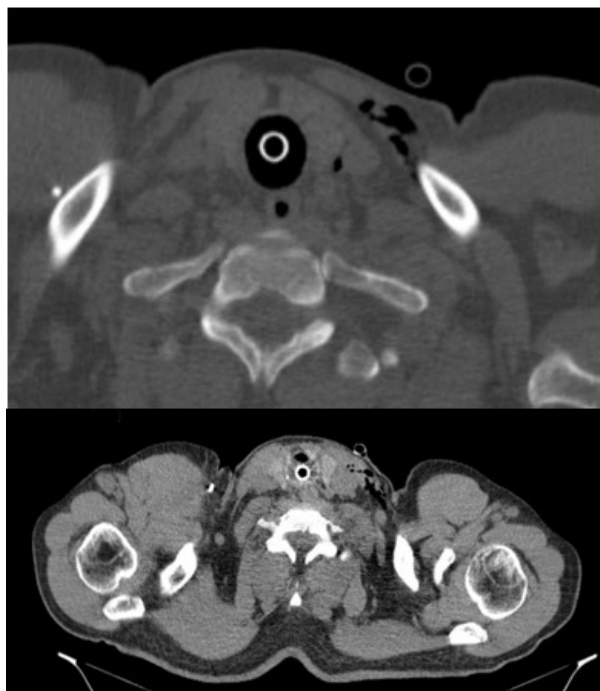

Figure 3 – Data of spiral computed tomography of the neck and chest: gas in the anterior-upper parts of the mediastinum (left); gas accumulation in the interaponeurotic space of the neck (right)

After performing an additional instrumental examination the diagnosis was made: «an acute odontogenic limited osteomyelitis of the upper jaw from 2.7 teeth. phlegmon of the left pterygoid-maxillary space, left subtemporal, temporal, pterygoid-palatine fossa, perilaryngeal, chewing spaces, vasodilator-nerve bundle of the neck to the left, left lateral interaponeurotic space of the neck. Anterior-upper mediastinitis. Systemic inflammatory reaction syndrome».

On 03.02.2018 at 14: 40 together with a thoracic surgeon the third operation «mediastinotomy of the anterior-upper parts of the mediastinum, opening of the left lateral interaponeurotic space of the neck» was performed. At 18:00 due to suspicion of immunodeficiency the patient was examined by an immunologist, Doctor of Medical Sciences, Professor of the Department of Maxillo-facial Surgery and Dental Surgery of St.

Petersburg State University V. K. Kozlov. It was recommended to perform laboratory tests (clinical analysis of blood with leukocyte formula daily, CRP, procalcitonin, fibrinogen level), to prescribe infusion immunocorrectors (Reamberin intravenously daily 1-2 times 400 ml in 10-12 infusions; Cycloferon intramuscularly daily 1 ml 6-8 injections). With the development of sepsis add Roncoleukin (IL-2 people recombinant) 0.5 mg to the above scheme in 250 ml of physiological solution with albumin intravenously drip slowly in 3-5 infusions every other day.

On the second day of hospitalization on 04.02.2018 patient L. was examined in the Department of anesthesiology, resuscitation and intensive care: the patient was conscious, removed from drug sedation, contacted, in clear consciousness. Heart rate was 66 beats/min, blood pressure was 120/65 mm Hg, frequency of respiratory movements – 12/min, body temperature – 36.7 °C. Nutrition was through a nasogastric tube.

Locally moderate edema persisted in the area of postoperative wounds without a tendency to increase. There was no smell after removing the bandages, the soft tissues in the bottom of the wound were bright pink, bleeding, palpation was painful. Purulent swelling was not detected during finger examination. Inflow and outflow washing of wound passages with isotonic sodium chloride solution, antiseptic treatment of postoperative wounds with 0.05 % chlorhexidine bigluconate solution was performed. The wounds were abundantly filled with Levomekol ointment, an aseptic gauze bandage was applied.

To drug therapy added: in order to maintain an optimal acid-base state of Mafusol (Potassium Chloride+Magnesium Chloride+Sodium Chloride+Sodium fumarate) 500 ml, neuroprotector Cytoflavin 10 ml, Propofol 50 ml – for sedation.

06.02.2018 (4-th day of stay in the Department of anesthesiology, resuscitation and intensive care) in the process of dynamic observation of the patient an increase in crepitation of soft tissues in the right supraclavicular and subclavian areas was revealed, accompanied by small edema, hyperemia of the skin. A control CT scan of the chest was urgently performed where the spread of inflammatory infiltrate, a soft tissue emphysema to the lower parts of the anterior mediastinum, to the posterior mediastinum was revealed (fig. 4).

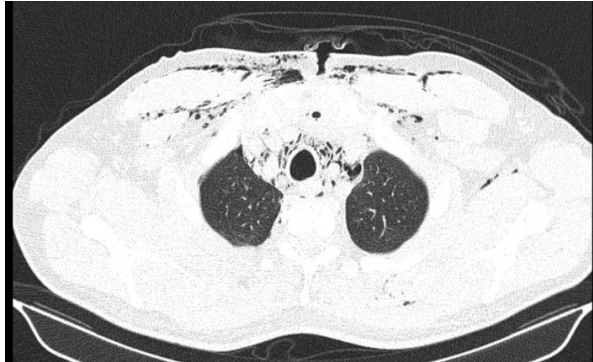


Figure 4 – Breast CT data – the spread of gas, inflammatory infiltration into the anterior-inferior mediastinum, posterior-superior mediastinum, intercostal spaces

07.02.2018 (5-th day of stay in the Department of anesthesiology, resuscitation and intensive care) during the consultation the diagnosis was made «an acute odontogenic limited osteomyelitis of the upper jaw from 2.7 teeth. Phlegmon of the left pterygoid-maxillary, left perilaryngeal, chewing spaces, left subtemporal, temporal, pterygoid-palatine fossa, neurovascular bundle of the neck on the left, left and right lateral interaponeurotic spaces of the neck. Anterior-upper, anterior-lower, posterior-upper mediastinitis. Sepsis.» A decision was made to manage the patient under the “Sepsis” program.

Cultures were taken from postoperative wounds for the second time. Bacterioscopy revealed G (-) sticks (presumably *Bacteroides* spp., *Fusobacterium* spp.), cocci (according to the results of cultures – polyresistant *Enterococcus faecium*, titer  $10^8$  CFU/ml, sensitive exclusively to Vancomycin). Also three-component antibacterial therapy (Sultasin+Metrogil+Amikacin) was replaced with a one-component (Meronem 1.0, every 8 hours intravenously through an infusomat), Roncoleukin was added 1 ml per day and Insulin 4 units. In laboratory blood parameters: albumin: 45.3 (norm 55.8 – 66.1 %),  $\alpha$ 1-globulin: 7.9 (norm 2.9 – 4.9 %),  $\alpha$ 2-globulin: 20.9 (norm 7.1 – 11.8 %), total protein, g/l: 62 (norm 64 – 82 g/l), C-reactive protein (CRP) 68.24 mg/l (norm 0-10 mg/l), procalcitonin (PCT), 0.5 ng/ml.

It was decided to perform revision of previously opened cellular spaces, necrectomy, opening and drainage of gas accumulations, infiltrate



in the anterior-inferior and posterior-superior mediastinum (fig. 5) under general anesthesia.

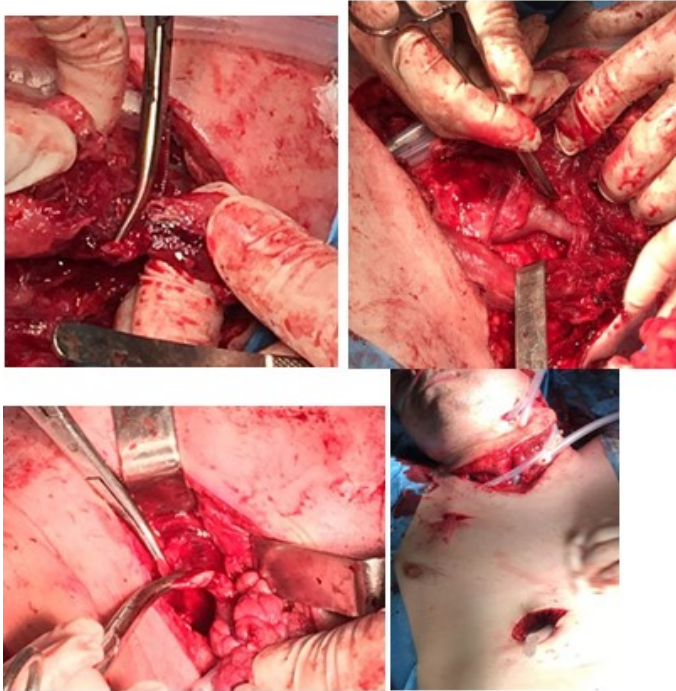


Figure 5 – The course of the third operation: necrectomy of the non-viable part of the left nodding muscle (top left); revision of the neurovascular bundle of the neck on the left (top right); extirpation of the non-viable left submandibular salivary gland (bottom left); drainage of the anterior and posterior mediastinum (bottom right)

In connection with the prolonged artificial ventilation of the lungs a tracheostomy was performed on 09.02.2018 (the 7-th day of stay in the Department of anesthesiology, resuscitation and intensive care). After the tracheostomy- the absence of respiration in the lower parts of the right lung was revealed, the occurrence of spontaneous pneumothorax was suspected that was confirmed radiologically (fig. 6). A thoracic surgeon performed

thoracocentesis of the right pleural cavity, active drainage by Redon was established.

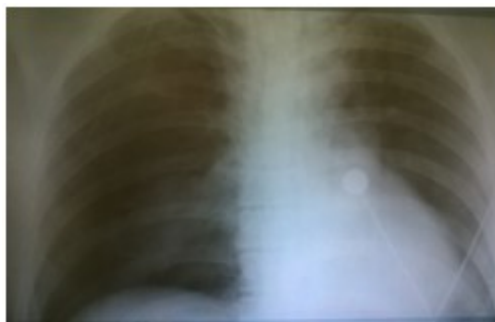

Figure 6 – Collapse of the right lung

In connection with the appointment of Meronem the patient had an increase in the level of hepatic transaminases from 10.02.2018 (the 7-th day of stay in the Department of anesthesiology, resuscitation and intensive care), the values reached a maximum on 14.02.2018 (ALT 238 units / l, AST 323 units/l followed by a decrease in their level). The level of bilirubin during the treatment was within the physiological norm. Typically the dressings are moderately impregnated with serous discharge, granulations are determined in the wound.

On the 8-th day of his stay in the Department of anesthesiology, resuscitation and intensive care on 10.02.2018 during the dressing the patient developed a severe coughing attack which determined a further increase in soft tissue emphysema that later spread to the level of the scrotum on the left.

On 12.02.2018 (10-th day of treatment), a control breast CT scan was performed where soft tissue emphysema was determined, the right lung was straightened. A dressing was also performed: the accumulation of blood clots as a potential source of infection was evacuated from the left parotid-chewing region, the wound was drained by tubular drains.

On 13.02.2018 (11-th day of treatment) the patient was transferred to independent breathing after removal of pleural drainage.

14.02.2018 (12-th day of treatment) active granulation of postoperative wounds was noted against the background of conservative therapy, daily dressings with Levomekol, Levosin ointment, washing of the

drainage system with solutions of 0.1 % Lavacept, 0.9 % sodium chloride cleansing of the wound from necrotic tissues, fibrinous plaque. It was decided to perform secondary surgical treatment with soft tissue plastic elements for the speedy closure of the skin defect, creating conditions for optimal healing of postoperative wounds (fig. 7).

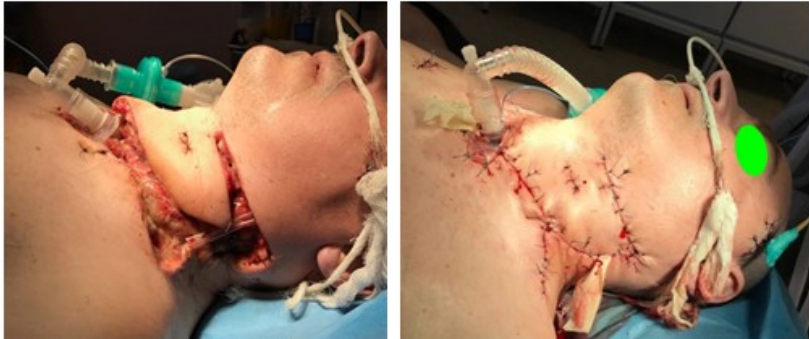

Figure 7 – Appearance of the patient: before surgery (left); after secondary surgical treatment with elements of plastic soft tissues (right)

On the 13-th day of treatment in the conditions of acute respiratory viral infection on 02.15.2018 the patient was conscious, withdrawn from drug sedation, in contact, consciousness was clear. Moderate swelling in the area of postoperative wounds were without a tendency to increase, the skin flaps were without signs of blood supply disorders, sutures in the area of postoperative wounds were perfect. There was no smell after removing the bandages. Bandages were performed with the application of wet-drying dressings with 0.05 % Chlorhexidine bigluconate solution. Early activation of the patient began: coordination of movements was completely preserved, the patient moved independently around the ward, executed commands.

On the 14-th day of treatment, on 16.02.2018, drainage was removed from the anterior mediastinum, decanulation of the tracheostomy tube was performed. The edges of the wound after removal of the cannula were tightened with a band-Aid bandage. The wound in the epigastric region was sutured by Donati sutures under local anesthesia. The nasogastric tube was removed, the patient was transferred to self-feeding. Postinjection phlebitis of the right ulnar vein was developed, which was later stopped by compresses with Troxevasine, the semi-alcoholic

compresses. Tracheostomy closure was performed on the 16-th day of inpatient treatment. Since 19.02.2018 positive dynamics was noted: postoperative wounds were partially under bandages, there was no wound discharge, wounds were epithelized. Emphysema of the soft tissues of the trunk was without a tendency to spread.

On the 25-th day of treatment, on 27.02.2018, complete removal of sutures from postoperative facial wounds, partial removal of sutures from the neck was performed (fig. 8). In laboratory blood tests the leukocyte level was normal ( $4.3 \times 10^9/l$ ), the acceleration of ESR to 40 mm/h was maintained, the glucose level was slightly increased (5.4 mmol/l). The patient was discharged in a satisfactory condition under the supervision of a surgeon, a dental surgeon at the place of residence with the diagnosis: «an acute odontogenic limited osteomyelitis of the upper jaw from 2.7 teeth. Phlegmon of the left pterygoid-maxillary space, the left subtemporal, temporal, pterygoid-palatine fossa, the left perilaryngeal, chewing regions, the neurovascular bundle of the neck on the left, the left and right lateral interaponeurotic regions of the neck. Anterior-upper, anterior-lower, posterior-upper mediastinitis. Sepsis. Post-injection phlebitis». An examination by the attending maxillofacial surgeon was recommended in 7 days.

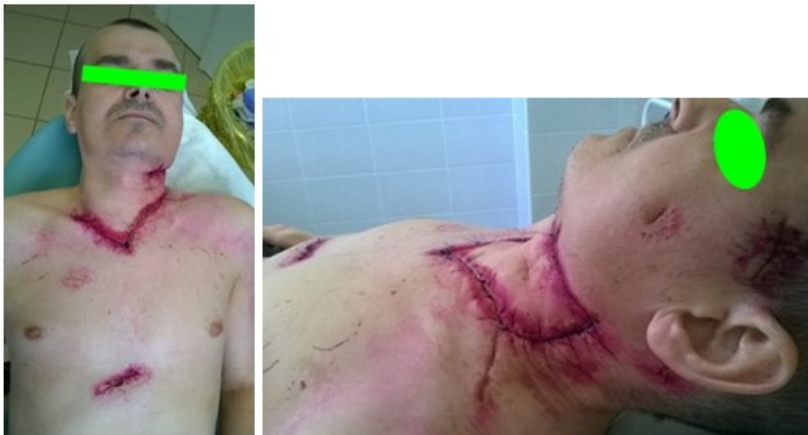

Figure 8 – Appearance of patient L. at discharge from the front (left); appearance of the patient L. at discharge on the left (right)

During the control examination after discharge on 06.03.2018 the final removal of sutures from postoperative wounds was performed. Also during the examination the forming contracture of the lower jaw was revealed (figure 9), in this regard physiotherapy treatment (mechanotherapy, magnetotherapy, electrophoresis with collagenase) was recommended to the patient.

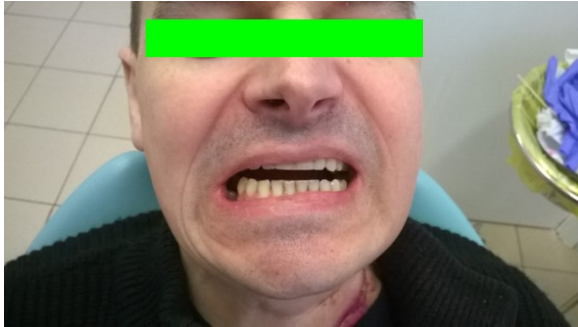

Figure 9 – Appearance of the patient on the 7-th day after discharge – forming contracture of the lower jaw on the left

In conclusion, it should be emphasized that only a multidisciplinary approach to the prevention, diagnosis and treatment of acute odontogenic infection can give a positive result. Surgical treatment and drug therapy of odontogenic infection should be considered as complementary components of the complex therapy of purulent-inflammatory diseases of the maxillofacial region.

Well-coordinated work in the hospital of a maxillofacial surgeon, an otolaryngologist, a thoracic surgeon, an anesthesiologist in conjunction with an immunologist, a clinical pharmacologist, a therapist, a physical therapy doctor can reduce the mortality rate in the development of formidable complications of acute odontogenic infection such as odontogenic mediastinitis.

### **Bibliography**

[1] Korovin A.Ya., Maskin S.S., Marchenko N.V. Tactics of treatment of generalized infection in purulent mediastinitis [Text] // Mat.of the 3rd Congress of the Association of Surgeons. – Moscow, 2007. 123-124 p.

[2] Features of the clinic and results of treatment of patients with acute odontogenic infection based on the materials of the St. Petersburg City maxillofacial hospital for 30 years (1965-1995) [Text] / V. A. Kozlov, N. K. Artyushenko, L. P. Petrova, F. I. Shulman // collection of works of the department and clinic of Maxillofacial Surgery with a course of orthodontics. – St. Petersburg., 1995. 14-18 p.

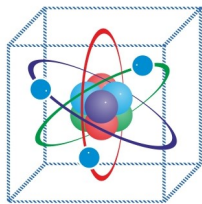
[3] Robustova T.G. Dynamics of frequency and severity of odontogenic inflammatory diseases for 50 years (1955-2004) [Text] / T.G. Robustova // Dentistry. – 2007. No. 3. 63-66 p.

[4] Ennker I.C. Management of sterno-mediastinitis [Text] / I.C. Ennker, J.C. Ennker // HSR ProcIntensiv Care Cardiovasc Anesth. – 2012. N four (4). 233-241 p.

[5] Sakamoto H., Aoki T., Kise Y. et al. Descending necrotizing mediastinitis due to odontogenic infections [Text] // Oral Surg. Oral Med. Oral Pathol. Oral Radiol. – 2000. Vol. 89, No. 4. 412–419 p.

© O.D. Maday, D.Yu. Maday, Yu.A. Shcherbuk, V.K. Kozlov, 2023





# ВЕСТНИК НАУКИ

Сборник научных статей по материалам  
Международной научно-практической конференции

## FUNDAMENTAL SCIENCE AND TECHNOLOGY



Издательство «НИЦ Вестник науки»

К-368-3



# FUNDAMENTAL SCIENCE AND TECHNOLOGY

Сборник научных статей по материалам  
XII Международной научно-практической конференции

**Часть 3**

14 апреля 2023 г.

Уфа 2023



**УДК 001**  
**ББК 72**  
**Ф 97**

**Ф 97**      **Fundamental science and technology / Сборник научных статей по материалам XII Международной научно-практической конференции (14 апреля 2023 г., г. Уфа). / В 3 ч. Ч.3 – Уфа: Изд. НИЦ Вестник науки, 2023. – 284 с.**

В сборнике представлены материалы XII Международной научно-практической конференции «Fundamental science and technology», где нашли свое отражение доклады студентов, магистрантов, аспирантов, преподавателей и научных сотрудников ВУЗов по химическим, техническим, экономическим, филологическим, медицинским и другим наукам. Материалы сборника актуальны для всех интересующихся перспективными и инновационными направлениями развития науки и техники и могут быть применены при выполнении научно-исследовательских работ, а также в преподавании соответствующих дисциплин.

Авторы опубликованных материалов несут ответственность за интерпретацию и изложение результатов научно-исследовательских работ, подбор и точность приведенных статистических данных, фактов, цитат, подлежащих открытой публикации.

Материалы размещены в сборнике в авторской правке.

При перепечатке материалов издания ссылка на сборник статей обязательна.

**УДК 001**  
**ББК 72**

© Корректурa и верстка ООО «НИЦ Вестник науки», 2023  
© Коллектив авторов, 2023